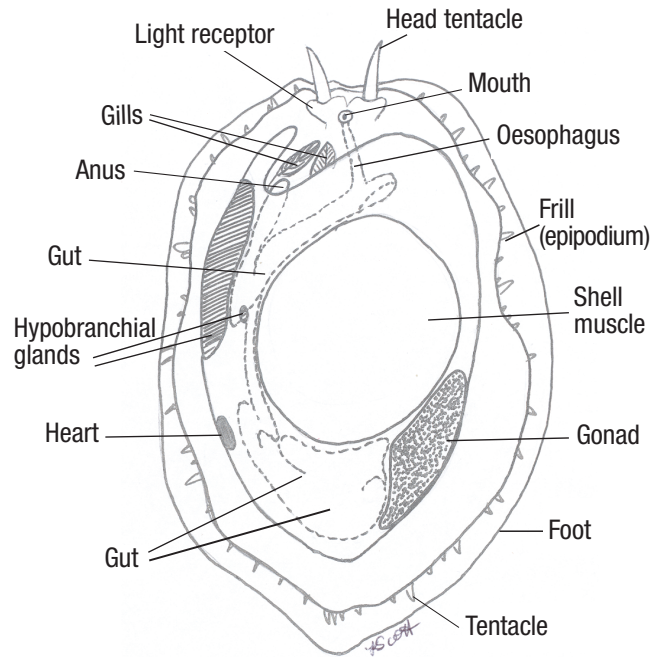


Anatomy—Mollusc




Abalone: greenlip (*Haliotis laevis*), blacklip (*Haliotis rubra*) and hybrid tiger (*Haliotis laevis* x *rubra*)

Source: K Scott



Ventral view of anatomy of abalone

Source: K Scott

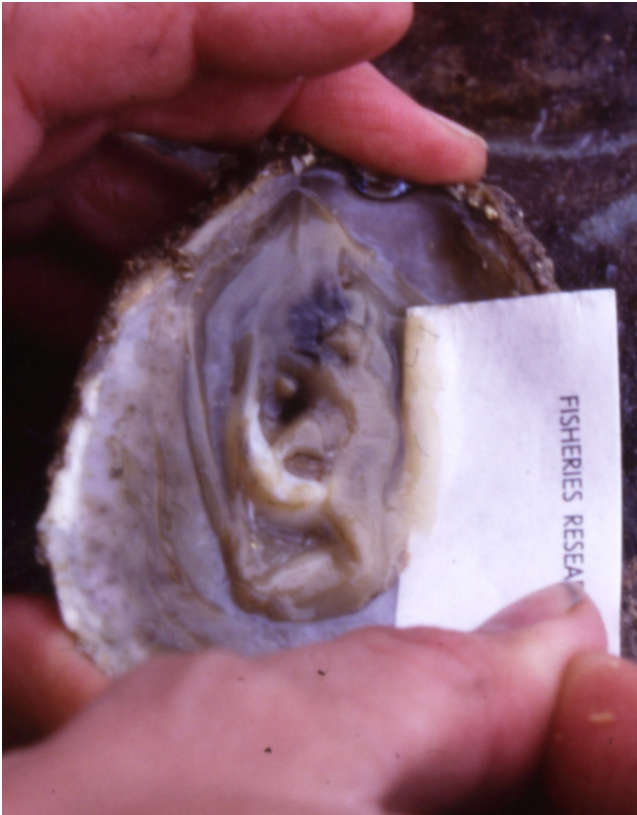

Dorsal view of anatomy of abalone

Source: K Scott

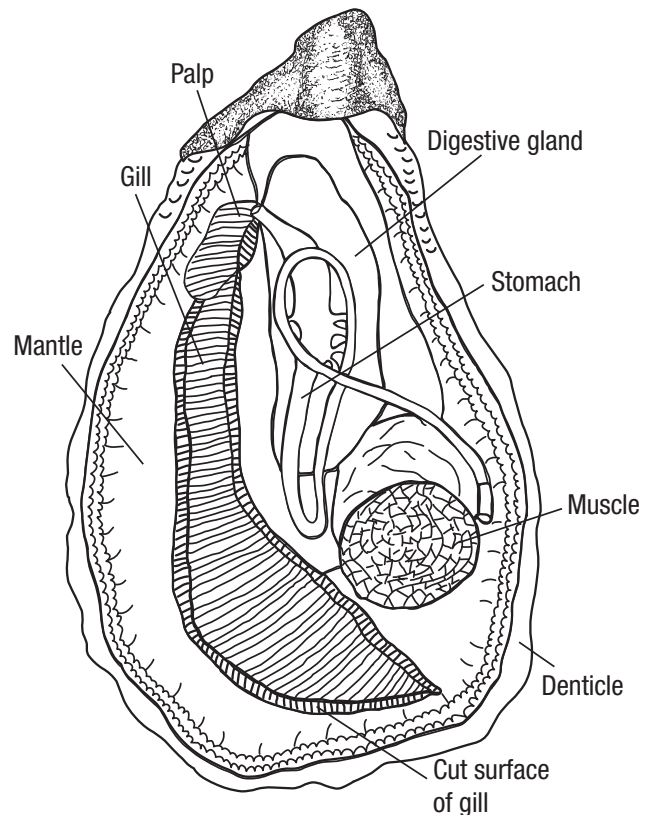


Anatomy—Mollusc continued



**Ventral view of New Zealand dredge oyster
(*Ostrea chilensis*)**

Source: B Jones



Anatomy of an oyster

Source: Aquatic Animal Health, Product Integrity Animal and Plant Health, AGDAFF



Australian Government
Department of Agriculture,
Fisheries and Forestry

Sourced from AGDAFF–NACA (2007) *Aquatic Animal Diseases Significant to Asia-Pacific: Identification Field Guide*. Australian Government Department of Agriculture, Fisheries and Forestry, Canberra.

© Commonwealth of Australia 2007

This work is copyright. It may be reproduced in whole or in part subject to the inclusion of an acknowledgment of the source and no commercial usage or sale.

